



5 Years follow up of the uncemented Global C.A.P. resurfacing shoulder prosthesis

PC Geervliet, MPJ van den Bekerom, C Visser, A van Noort

Introduction: Cementless humeral resurfacing arthroplasty is a bone conserving treatment option for patients with gleno-humeral osteoarthritis. Five year results of the Global CAP uncemented resurfacing shoulder arthroplasty (DePuy Synthes, Warsaw USA) were reported.



Patients: Forty-seven patients (12 males) with a mean age of 69 years (range 56-86) with primary gleno-humeral osteoarthritis with a sufficient rotator cuff, who underwent a cementless resurfacing arthroplasty between 2007 and 2009 at the department of Orthopedic Surgery in the Spaarne Gasthuis and Alrijne Hospital in The Netherlands were prospectively analyzed.

This study shows the mid term follow-up of the Global CAP resurfacing shoulder prosthesis.



Approach

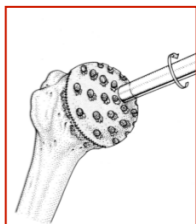
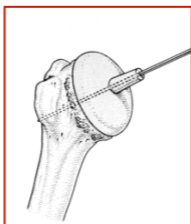
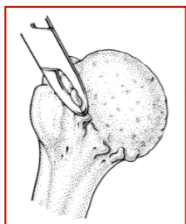
Deltopectoral approach

Lateral clavicle resection in 6 patients

Biceps tenodesis in 37 patients

> 20 degree exorotation; intra-tendon tenotomy of the subscapularis tendon

< 20 degree subscapularis tendon release





Results

Two and five year Constant Score, visual analogue pain scale (Vas), Dutch Simple Shoulder Test (DSST) scores improved significantly ($p < 0.05$) from baseline.

At this mid term follow-up radiographs were available for 37 shoulders in 35 patients. None of these patients showed loosening postoperatively. Three patients showed progressive glenoid erosion.

	Base line	2yr	5yr	
Constant	49	79	80	$p < 0.05$
Elevation	99	120	129	$p < 0.05$
Abduction	82	113	124	$p < 0.05$
Power	8	10	10	$p < 0.05$
Vas	65	35	31	$p < 0.05$
DSST	20	66	65	$p < 0.05$



Complication

One traumatic lesser tuberosity fracture, one intra-articular loose body due a fractured osteophyte, and one patient with a subscapularis tendon rupture.

Four patients were lost to follow up. One patient died and three patients were not able to attend at the follow-up appointments, due to other health related issues.

Revision

Seven patients (15%) had a revision operation, one patient had a low grade infection. One patient suffered of a massive rotator cuff rupture after a fall. One patient had an aseptic loosening of the implant. Four patients had persistent pain and loss of function with mild glenoid erosion and without signs of low grade infection



Conclusion

Cementless resurfacing arthroplasty is a viable treatment option for primary glenohumeral arthritis. Five year results indicate that the desired function and pain relief was achieved.

Discussion

- High rate of revision operation
- No control group